

## CASE STUDY

- 100% WOUND REDUCTION
- TOTAL HEALING IN 5 WEEKS
- 5 ACTIGRAFT APPLICATIONS

### PATIENT:

55 Year Old, White Male

### PAST MEDICAL HISTORY:

DM2, HTN, HL, Charcot Arthropathy

### LABS:

HgA1C 9.4 Otherwise Normal

### WOUND HISTORY:

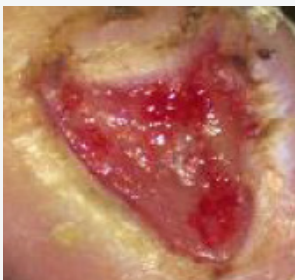- Right Great Toe DFU 1A
- 18 Week Old Ulcer
- ABI Results for the Affected Leg = 1.23
- 2.5 cm<sup>2</sup> x 0.3 cm, Minimal Serous/Sanguineous

### PAST TREATMENTS:

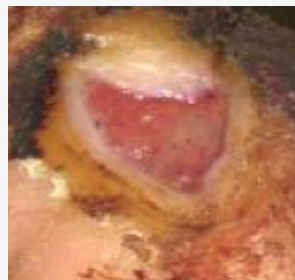Hydrogel, Wet-to-dry, Enzymatic Debridement with Regular Surgical Debridement

### ACTIGRAFT TREATMENT PROGRESSION:

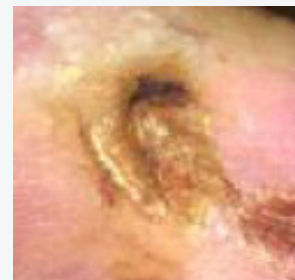Day 0



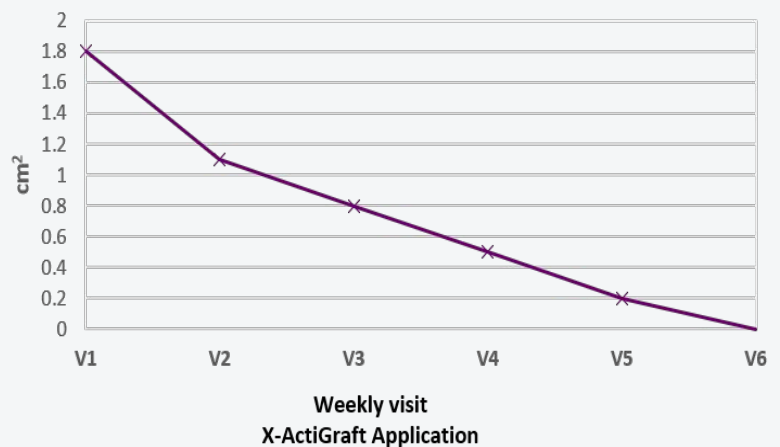
Day 14



Day 35



Wound Area cm<sup>2</sup>



V=Weekly Application

### OFFLOADING:

Boot